



**ÇORLU VATAN
HASTANESİ**

“ SİZİN HASTANENİZ ”

T.H.A.T.

29.01.2016

Dr. Aydın GÜRBÜZ

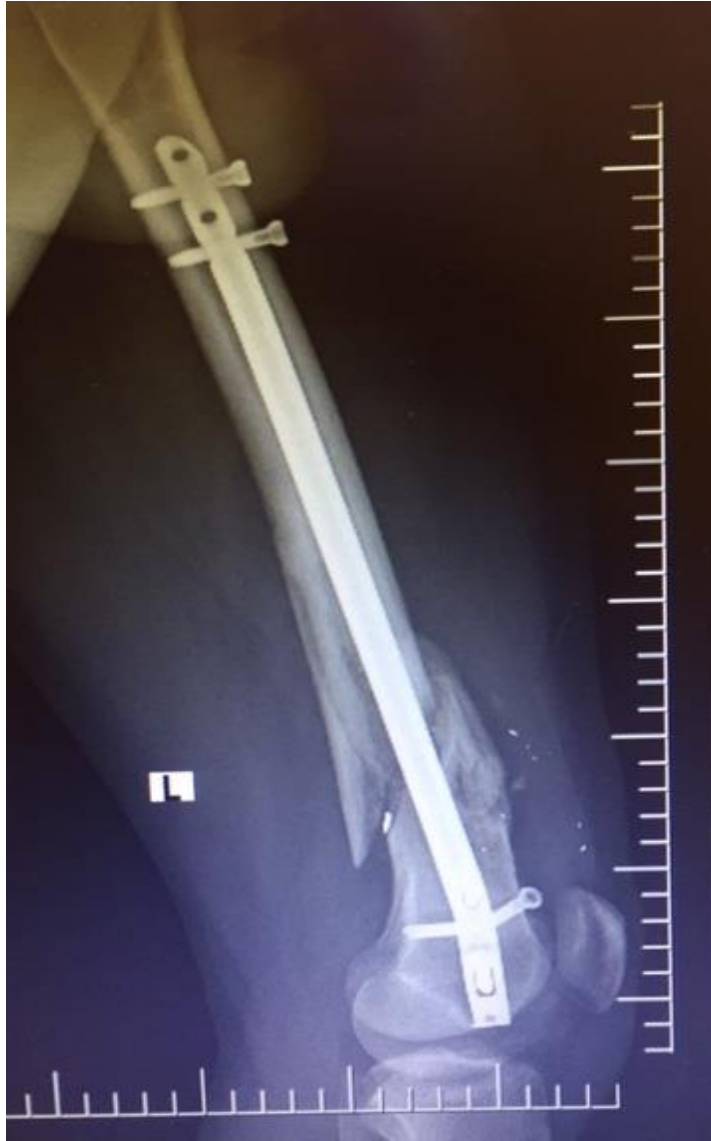ÇORLU

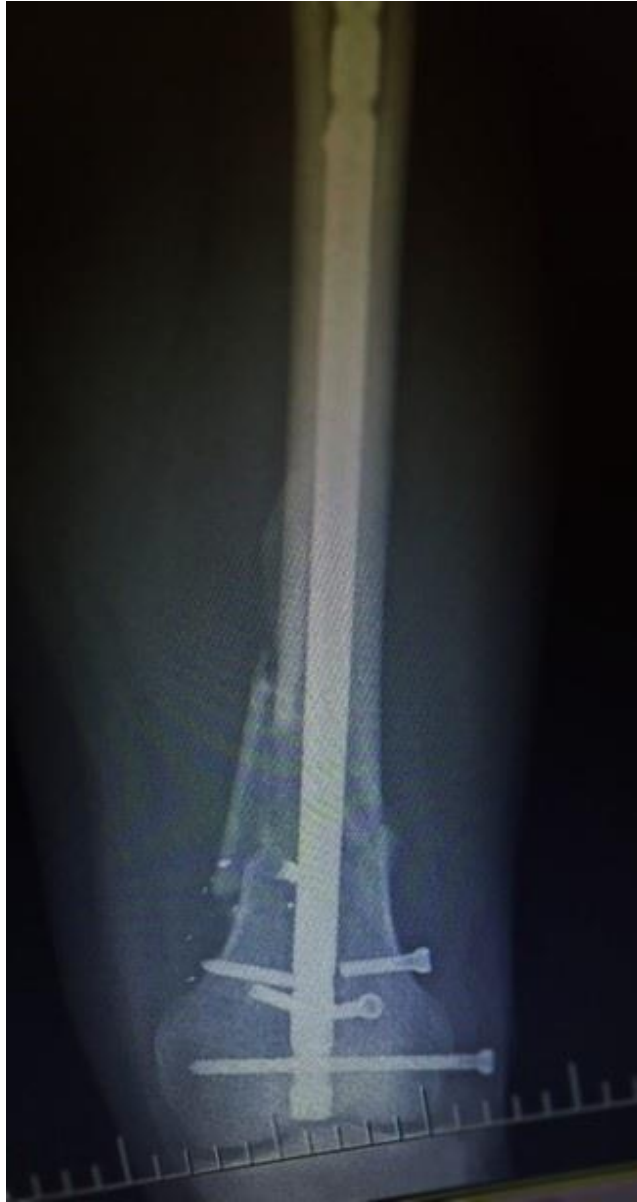T.E. 29 Y ERKEK HASTA

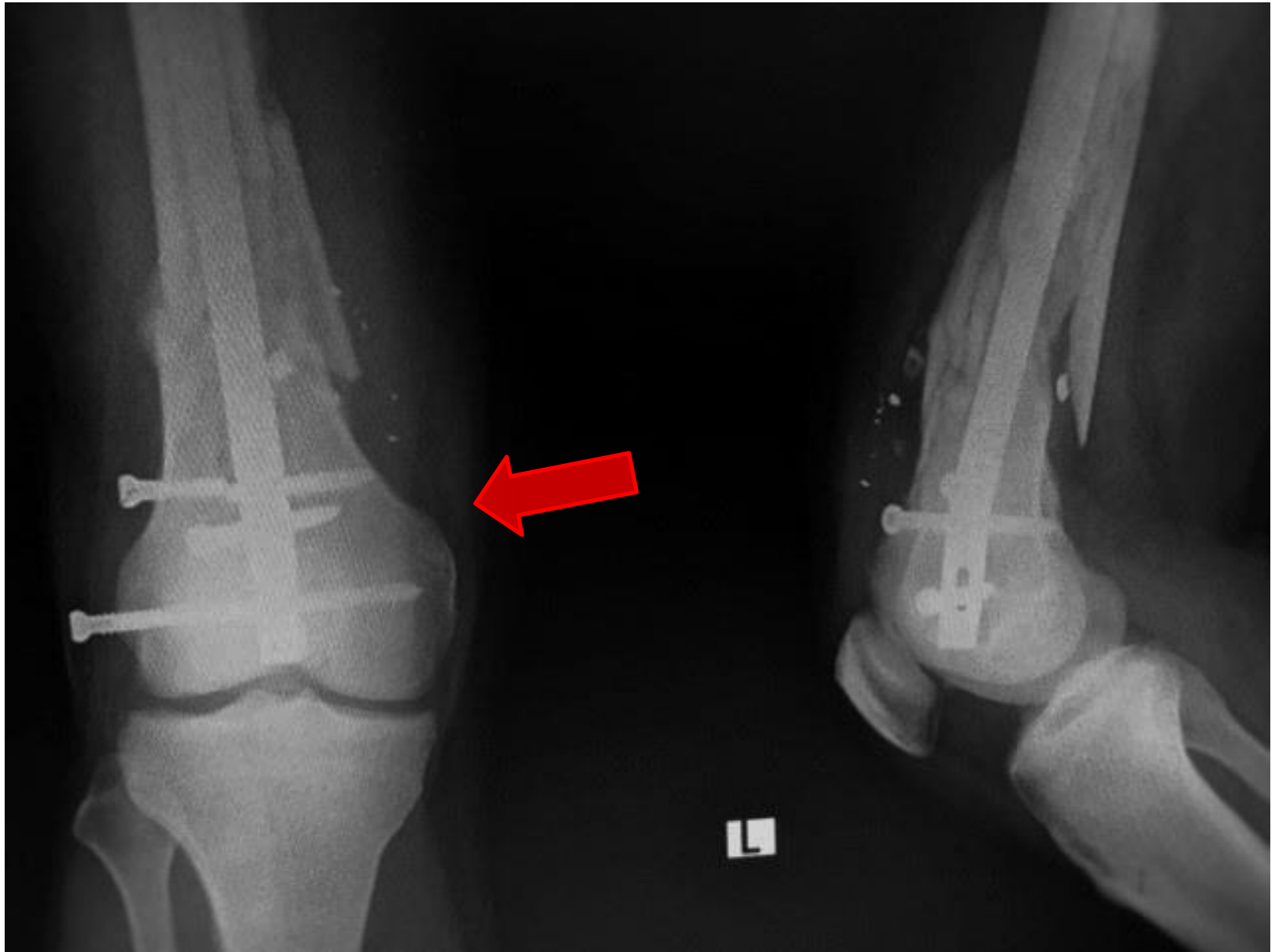
- ATEŞLİ SİLAH YARALANMASI
- FEMUR DİAFİZ DİSTAL 1/3 AÇIK PARÇALI KIRIK
- DIŞ MERKEZDE TEDAVİSİNE BAŞLANMIŞ
- POSTOP 3 AY HASTANEMİZE BAŞVURDU
- SOL ALT EKSTREMİTEDE AĞRI 3 cm KISALIK

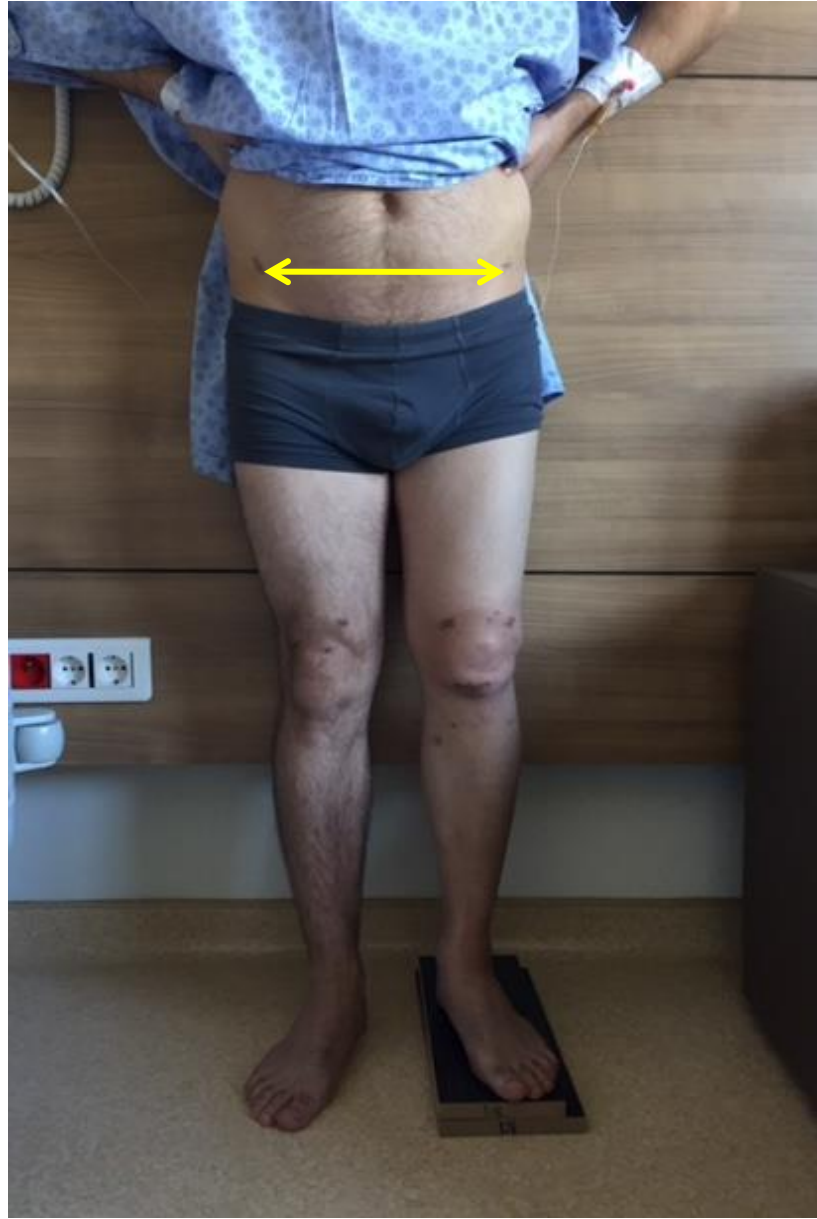TOPALLAMA

- FEMURDA NONUNION İMPLANT YETMEZLİĞİ

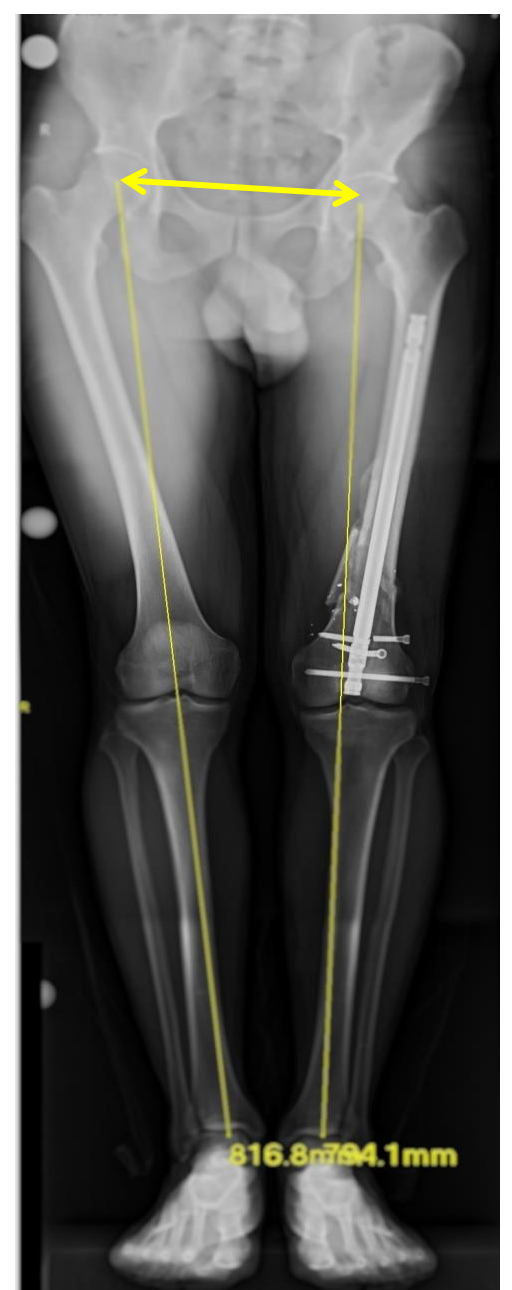







PREOP ORTORÖNTGENOGRAM

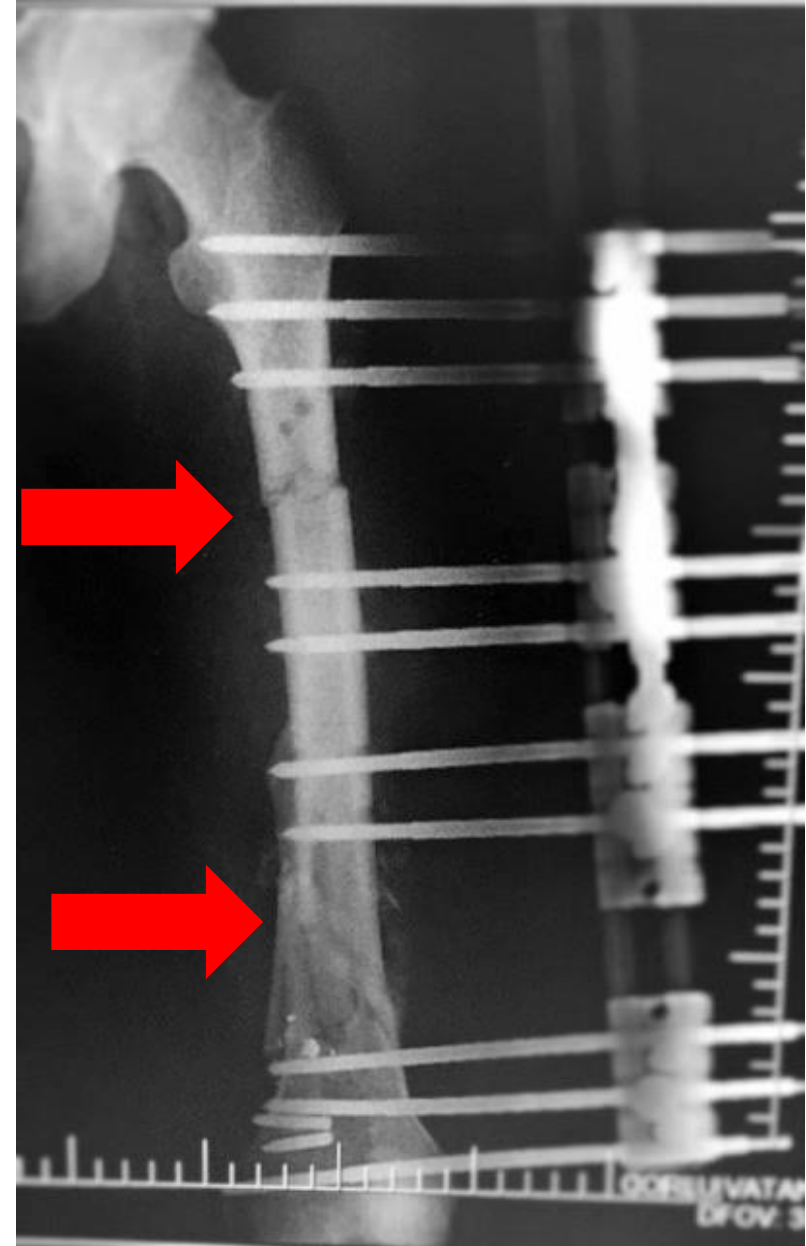


**İMPLANT
ÇIKARILMASI**

KORTİKOTOMİ

GREFTLEME

ORTHOFİX EF

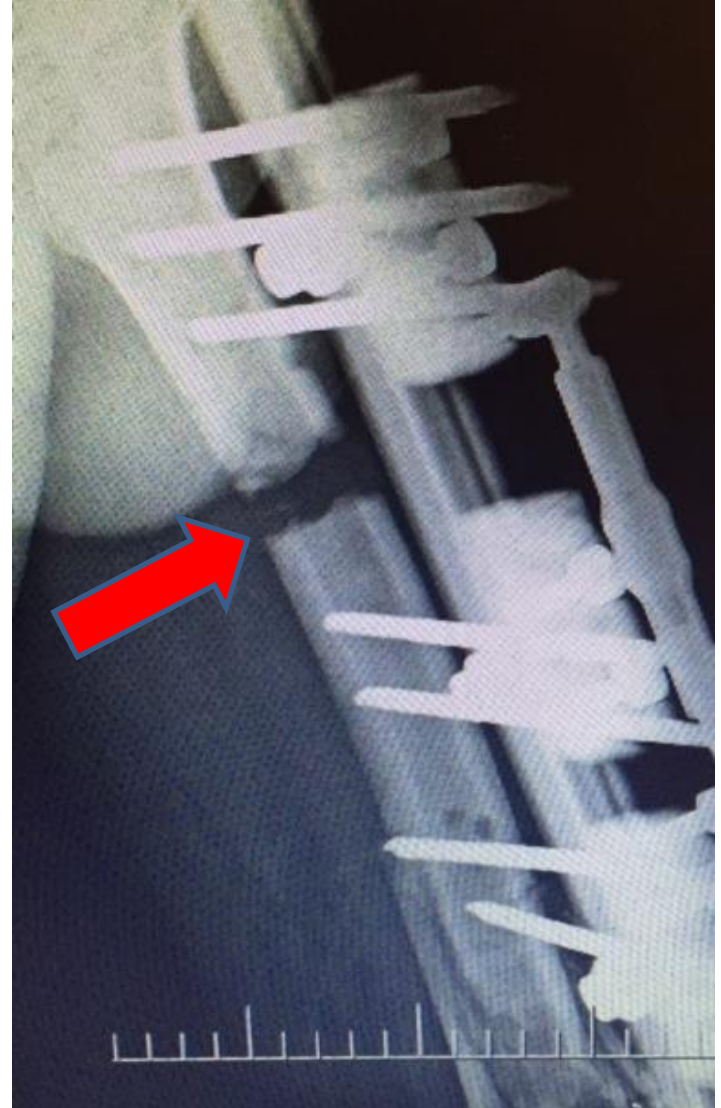
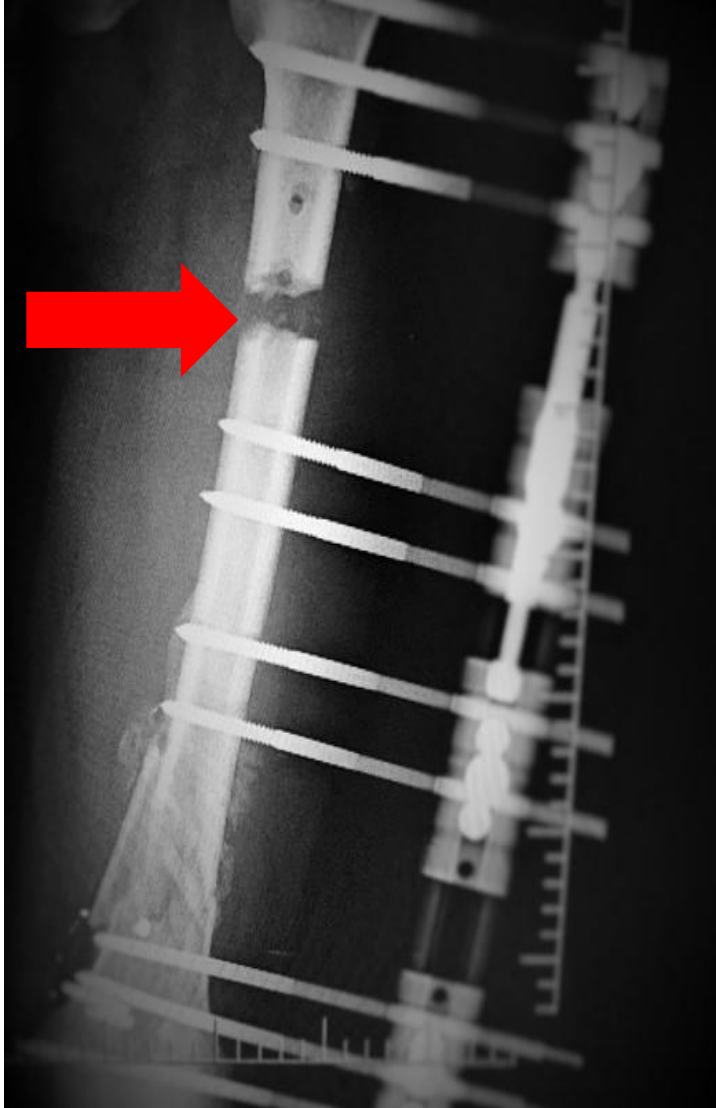


LATENT PERİYOD 10 GÜN

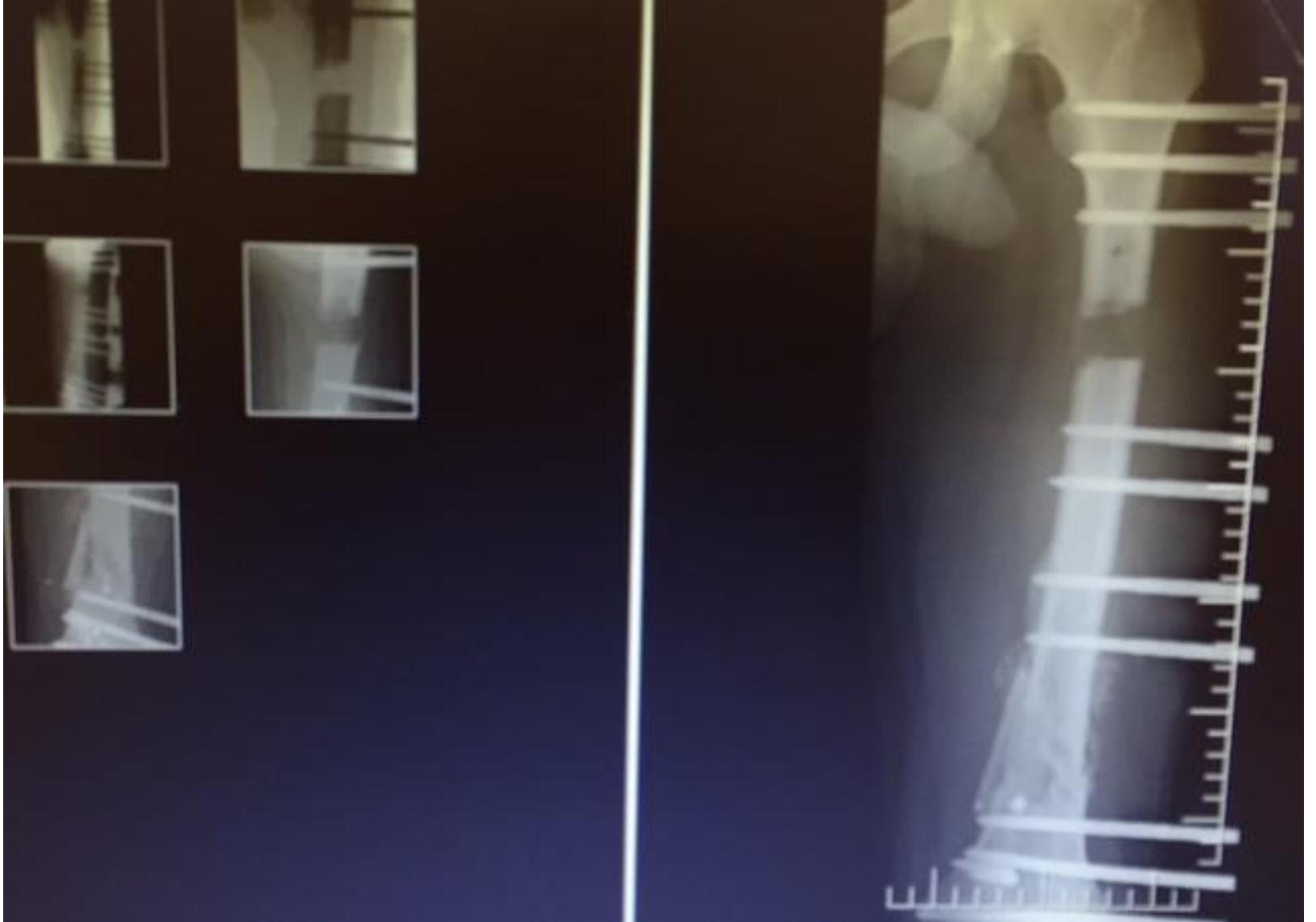**DİSTRAKSYON OSTEOGENEZİ İLE
30 GÜN UZATMA**

GÜNDE 1 mm

LATENT PERİYOD SONRASI 15 GÜN

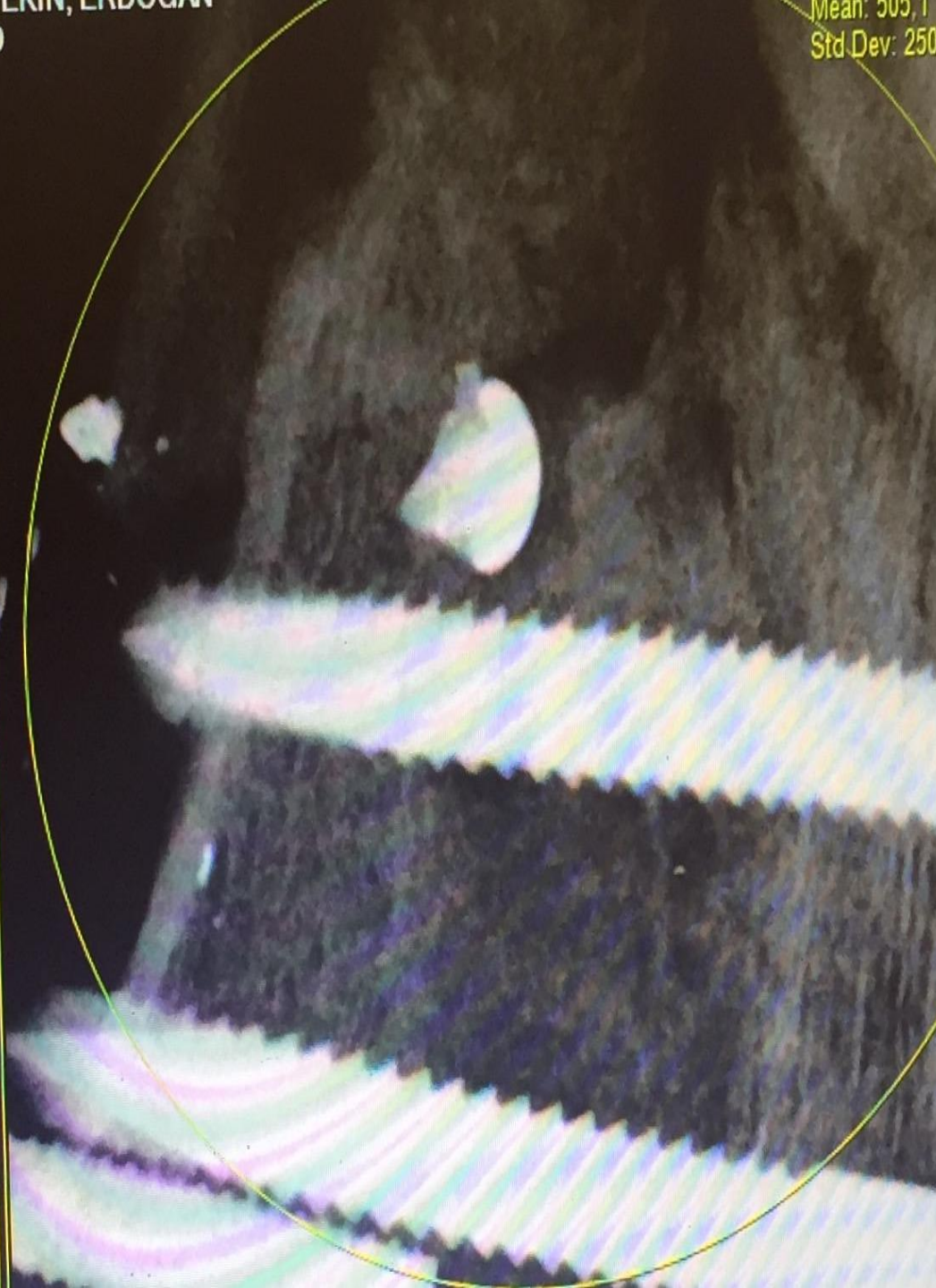
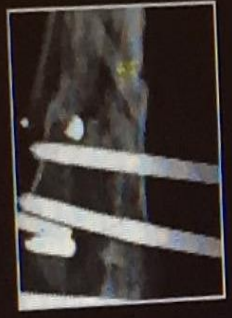
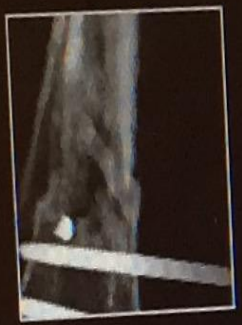
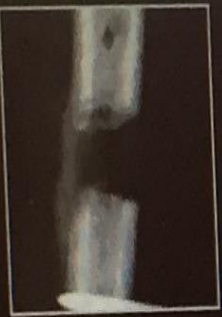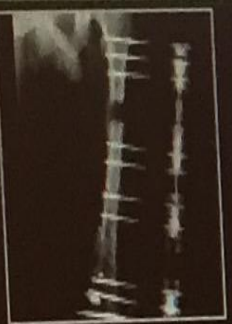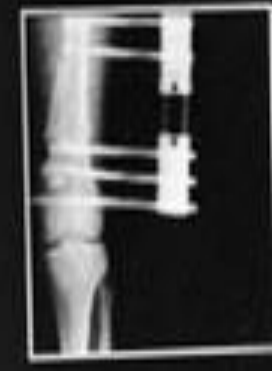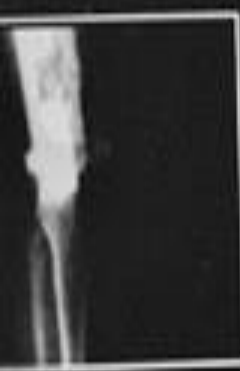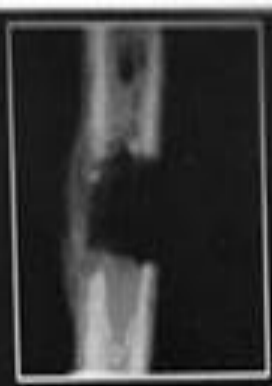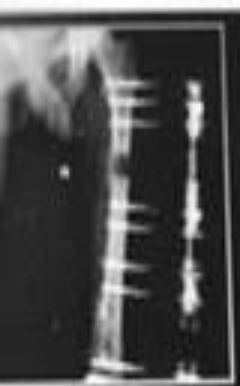30 GÜN



TERIN, ERDOGAN
0

Mean: 505, 1
Std.Dev: 250

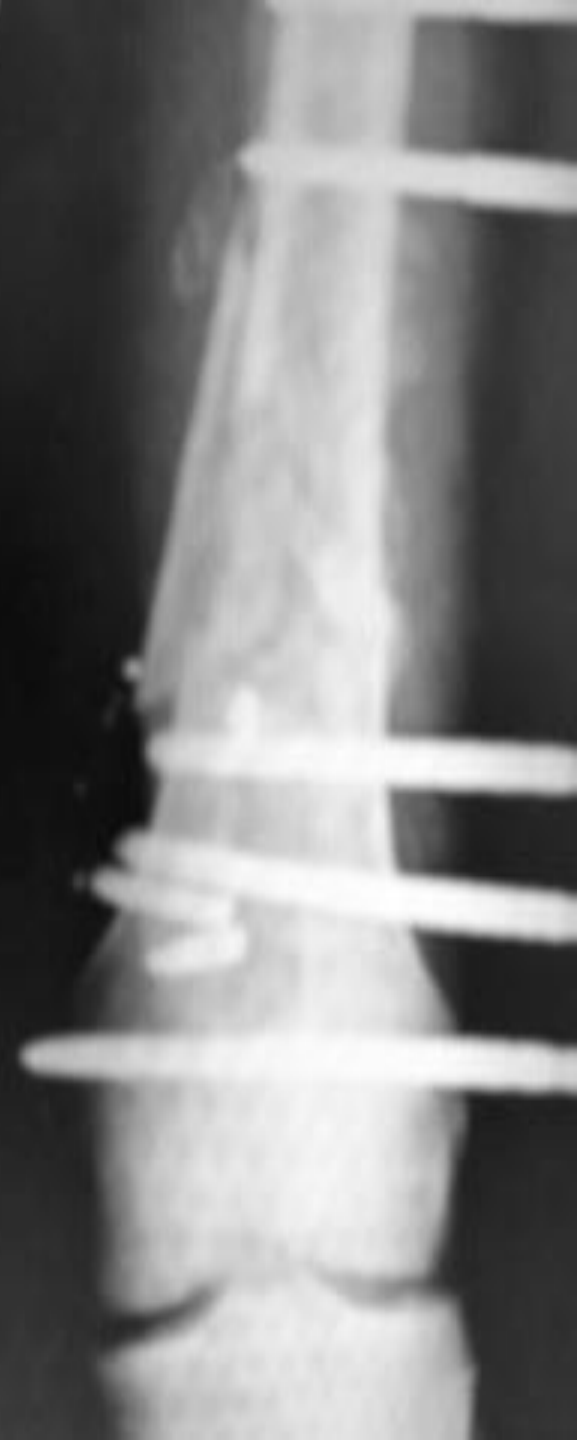



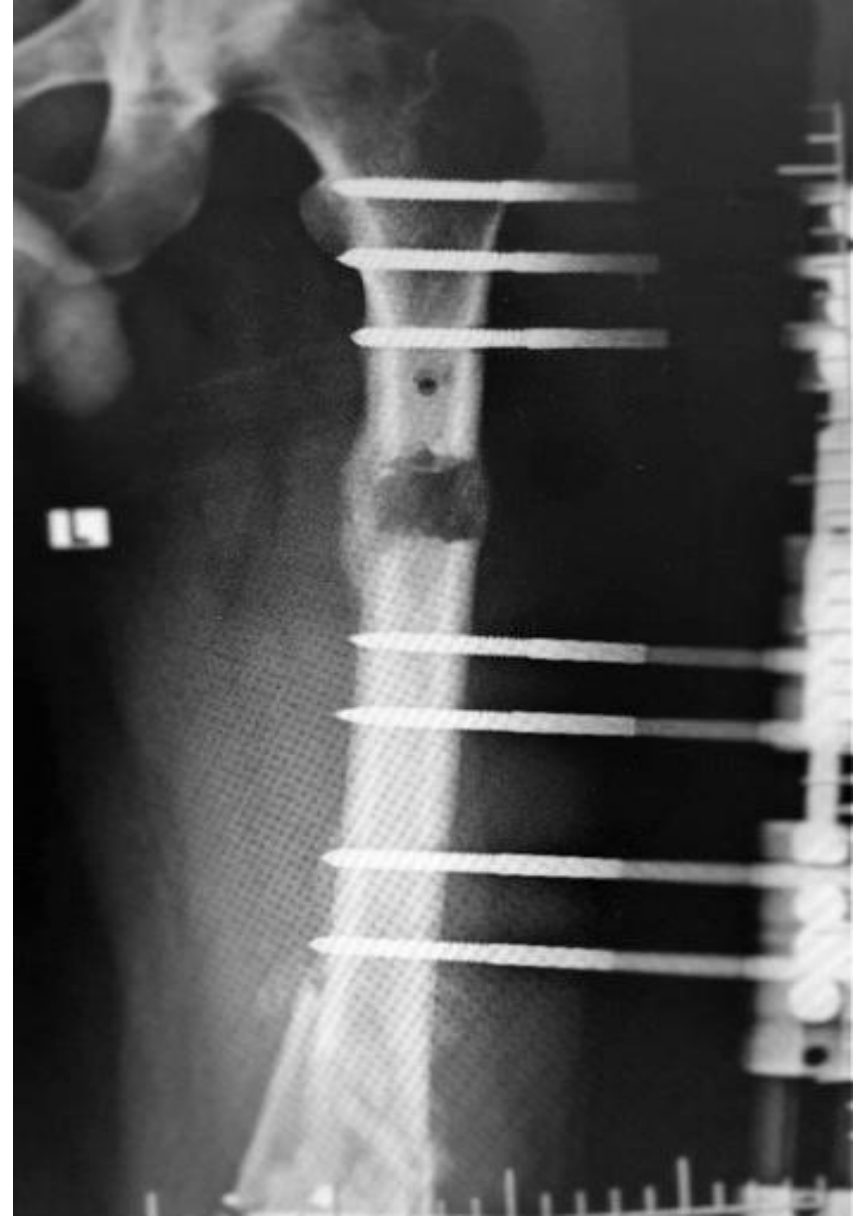
EXIN, ERDOGAN AY

0

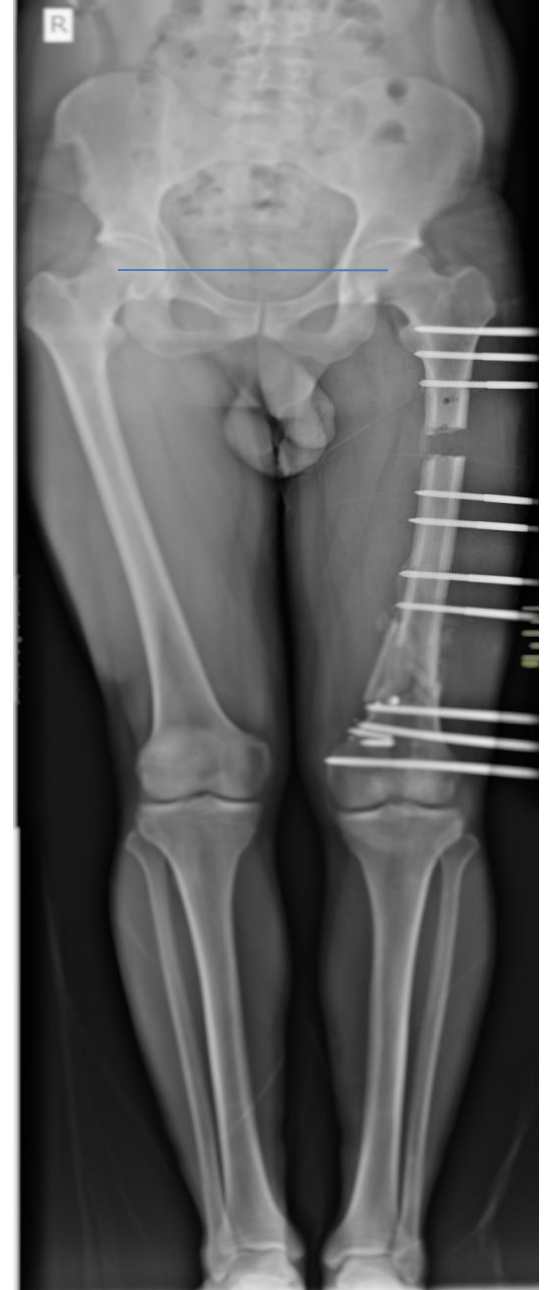L



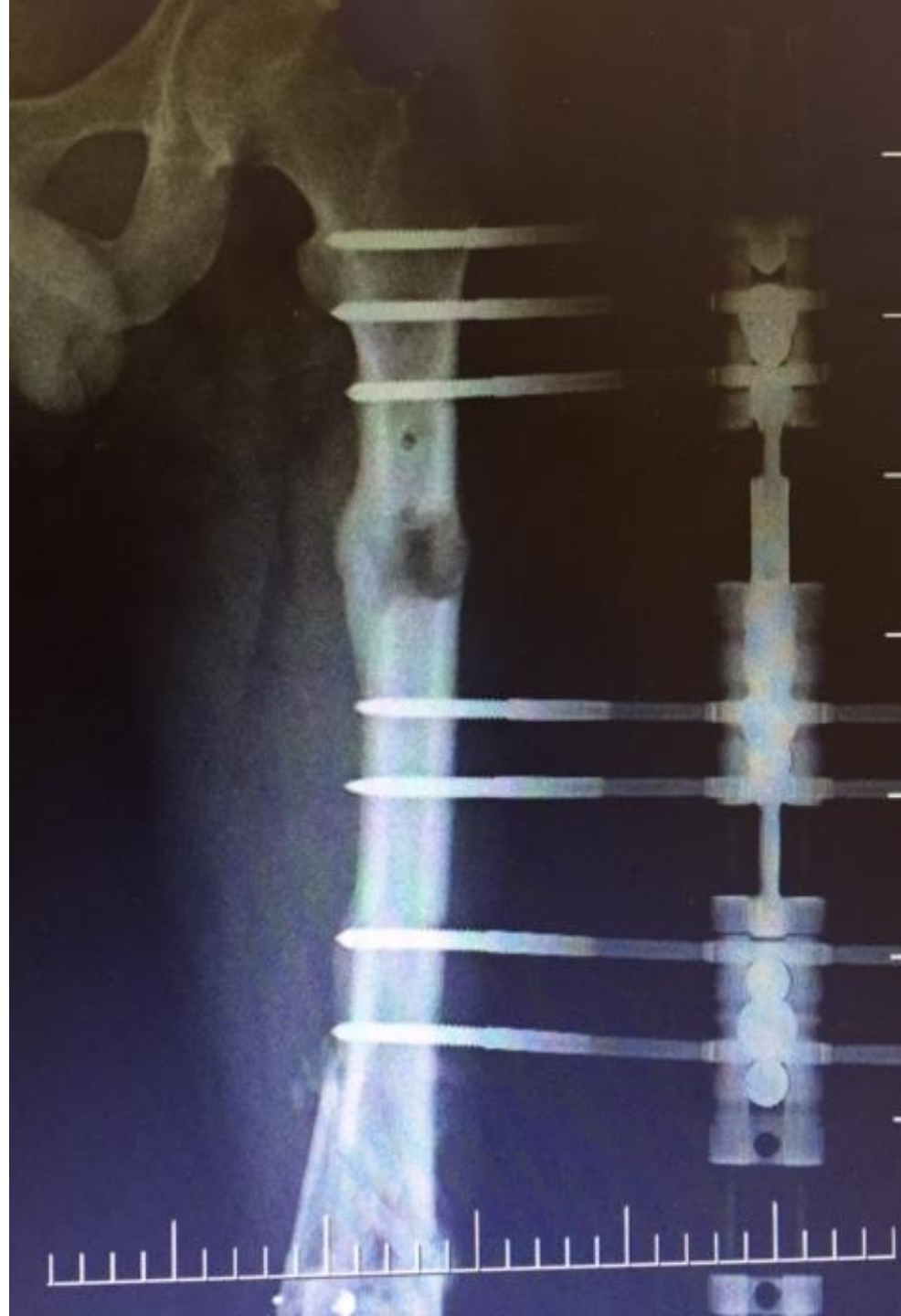BONE REGENERATE / 70 GÜN/



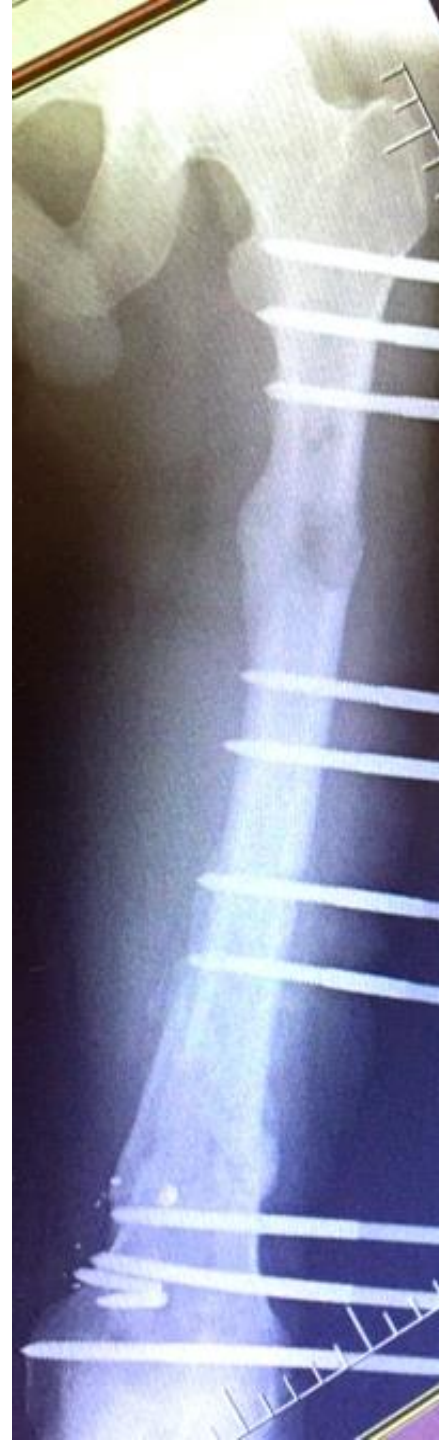REHABİLİTASYON PROGRAMI

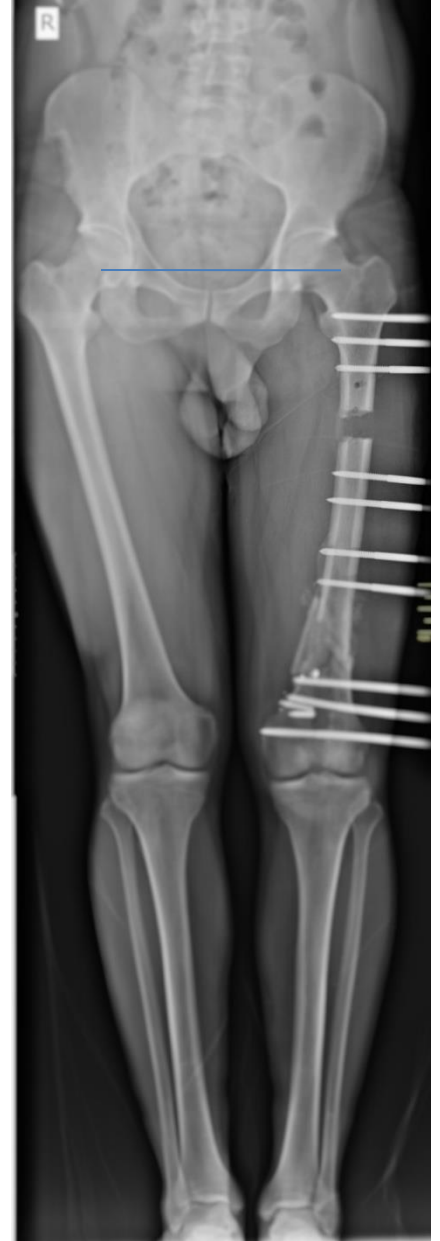
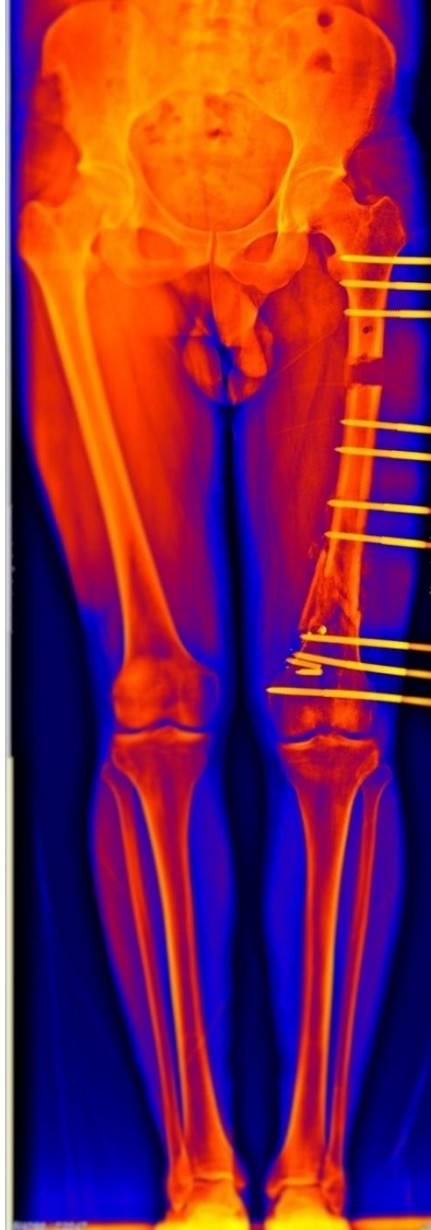
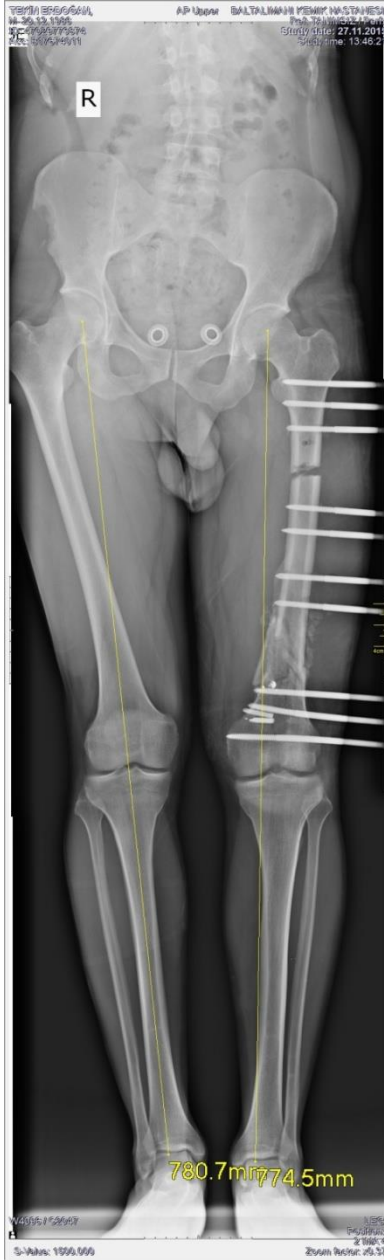
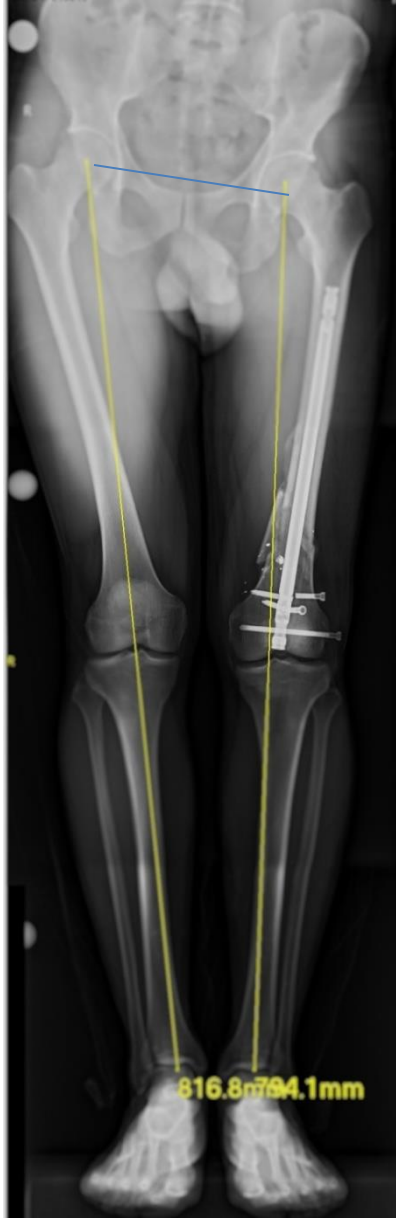POSTOP 97 GÜN

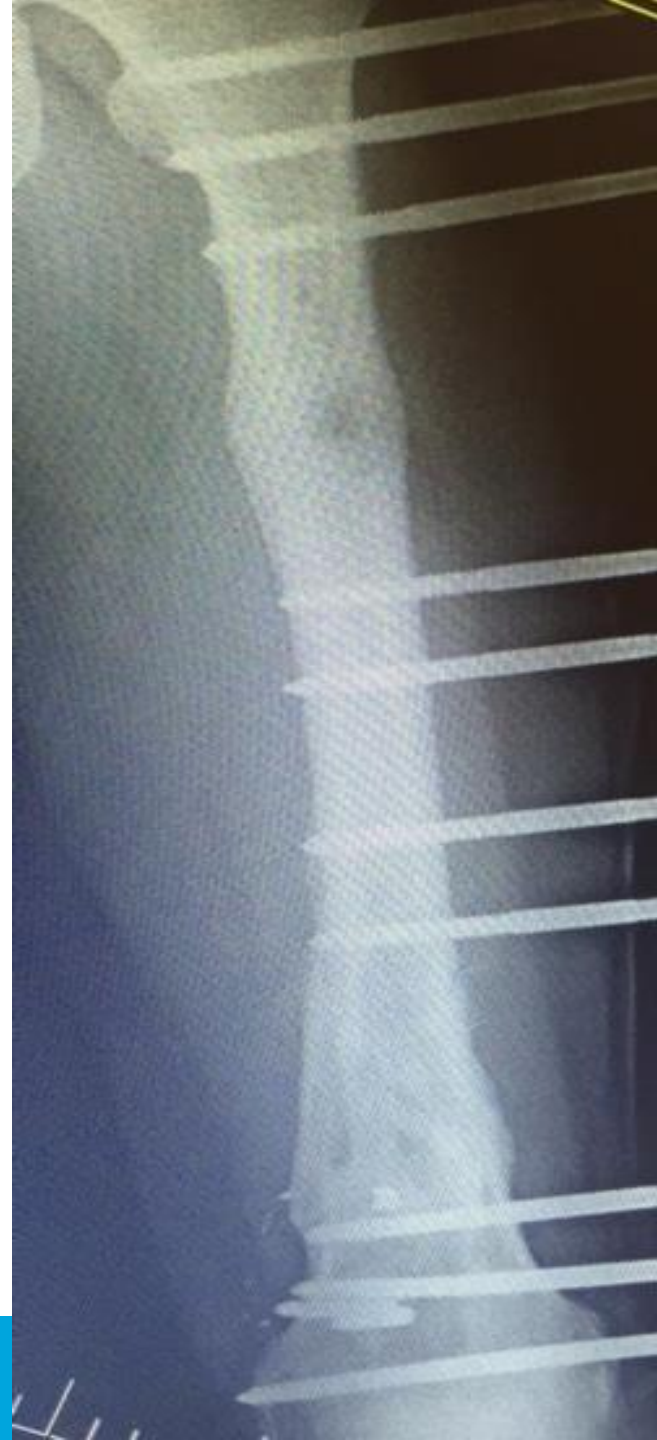

POSTOP 110 GÜN

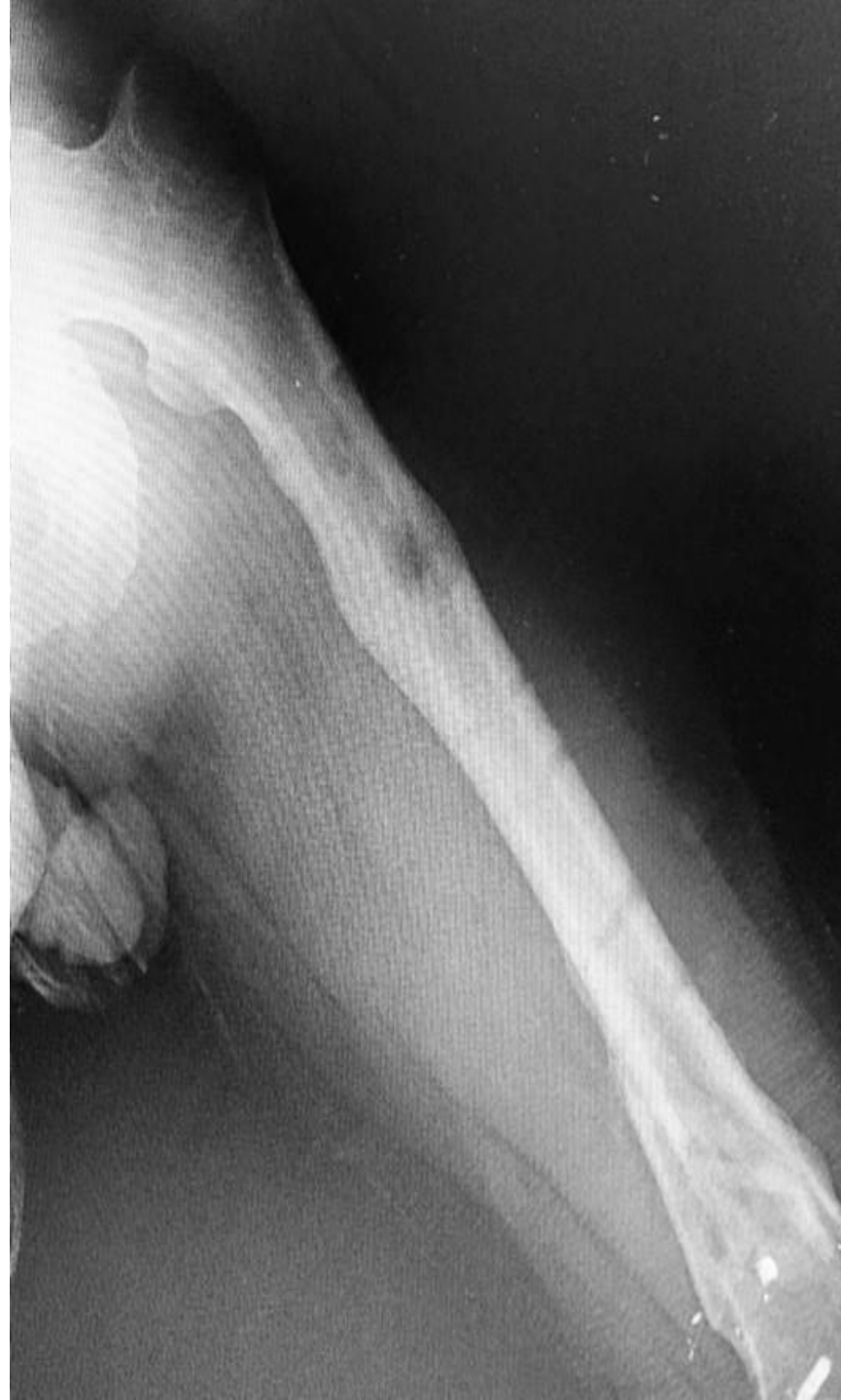



POSTOP 9. AY



**EKSTERNAL FİKSATÖR
ÇIKARILDIKTAN
SONRA**





TEŞEKKÜR EDERİM

Dr.AYDIN GÜRBÜZ